

## The Plastinated Abdominal Muscles Of The Goat As A Future Trend In Teaching Anatomy

Aly El-Deen A Basset, Hassan A Mohamed, Ahmed M EA Omar  
and Enas E A Ahmed

Anatomy and Embryology Dept., Fac. Vet. Med., Zagazig University

### ABSTRACT

The application of plastination technique as a new resource in anatomical education of abdominal muscles is of importance in the era of dwindling of cadavers for Veterinary Medical Education in Egypt due to the high cost of animals. Raising the advocacy for use of plastinates as adjunct to cadavers is needed to complement the learning and teaching of Veterinary Anatomy. The objective of this research was to describe the method of developing plastinated specimens of the goat abdominal muscles for educational purposes. A better understanding of abdominal muscles anatomy is relevant to gynecology, surgery and internal medicine. We recommend that the use of plastinated specimens is an excellent method for teaching abdominal muscles of goat.

### INTRODUCTION

The traditional method of preserving specimens is by saturation with a formalin based solution as open, wet preparations or by enclosure in glass or Perspex pots. Open specimens are unpleasant to work with it due to formalin vapors emitted and require lots of maintenance as rapidly deteriorate and dry out (1).

Plastination offers a method of keeping anatomical specimens without the usual problems associated with wet specimens as desiccation, mould and specific storage requirements. Plastinated specimens are clean and odorless, require minimal aftercare and can be stored on shelves or in display cases (2).

A further advancement in preservation of the body was made through the replacement of the remaining fluids in an embalmed body with a polymer-a process called plastination (3). This technique was invented by Gunther von Hagens, 1977. Since its introduction, it has gained wide acceptance throughout the world (4) and has been used to great advantage as adjuncts in the dissecting lab and are considered today's milestone in medical education (5). The

potential value of plastination in research is increasingly being appreciated.

Plastination may not reduce the use of experimental animals in the beginning, but will eventually replace them with plastinated models (6). Not only the plastinated models were durable (2), and invaluable didactic tool (3), but were also a safe (7) alternative to formalin preserved specimens which had proven health hazards (8).

### MATERIAL AND METHODS

The current work was carried out to prepare plastinated specimens of the abdominal muscles of the goat. Apparently healthy four goats of both sexes from native breeds were used with one to three years old. All goats included in this work received great care and merciful handling before being used in our preparations. The goats injected intravenous with xylazine Hcl (0.2mg/kg) (9).

The specimens were plastinated by Silicone 10 (S 10) technique which is the standard technique in Zagazig Plastination laboratory which was supported by a project from Higher Education Enhancement Program Fund (HEEPF, 2<sup>nd</sup> cycle 2004, code B-053-To). The procedure consists of the four main steps of plastination (fixation, dehydration, forced impregnation and hardening) (10), besides the specimen preparation and dissection (11).

#### Specimen Preparation and Dissection

The goats were injected via common carotid artery with 10% formalin solution for fixation. Then the trunk were separated, skinned, eviscerated and carefully dissected superficially and deeply to show the abdominal muscles.

#### Fixation

The prepared specimens were fixed for at least four weeks in 10% formalin and placed in a cold room (3-5°C); after the fixation was completed, the specimens were rinsed by running tap water before the next step for about 24 hours.

#### Dehydration

Dehydration was done in cold (-15 °C to -25 °C) acetone for three weeks. Acetone was changed every week. An acetone amount was ten times the specimen weight. Specimens were gradually shifted weekly from 80% to 85% to 90% to 95% acetone concentration. Dehydration was finished when the water content is less than 1%. For removal of fat for effective degreasing the dehydrated specimen was kept in acetone at room temperature for (48 hours).

#### Forced Impregnation

The silicone polymer S 10 was mixed with a curing agent BIODUR® S 3 (1 part S 3 and 100 parts S 10). The dehydrated specimen was submerged in the cold at (-15 °C to -25 °C) polymer mixture. In the 2<sup>nd</sup> day of immersion, the specimens were exposed to vacuum which must be increased gradually to boil the intermediary solvent (acetone), out of the specimen. Vacuum was completed when the pressure is around 5 mm Hg.

#### Gas - Curing (Hardening)

Finally the polymer inside the specimen has to be cured (hardened). This will be achieved by exposing the impregnated specimen to a gaseous hardener (BIODUR® S 6). Curing was completed at room temperature within two to seven days.

#### After Cure

For complete curing of the deeper regions inside the specimens. The partially-cured specimens should be kept in tightly sealed plastic bags for 6-8 weeks.

Nomenclature used in this study was adopted according to (12).

## RESULTS

#### Plastination

The plastinated trunk was clean, dry, odorless and resistant to handling. The texture of the plastinated muscles was harder and their color was slightly darker than the formalized specimen. The aponeurosis and tendinous structures had the same color of the formalized trunk but they were less pliable. All the abdominal muscles were easily demonstrated. This making the specimen useful for teaching the morphology of the abdominal muscles for surgical procedures, as well as. simply normal anatomy.

#### The morphology of the abdominal muscles

M. obliquus externus abdominis (Figs. 1/8 and 3,4/1) was the most extensive of the abdominal muscles. It was a broad sheath, irregularly triangular in shape, whose fibers were directed ventral and caudal, but in the area of the paralumbar fossa were seen to pass in a horizontal direction. It had a rather narrow fleshy portion and an extensive aponeurosis. It originated from the caudal border and lateral surface of the last eight ribs by digitations alternating with those of M. serratus ventralis thoracis in addition to the fascia over the intercostal spaces. They did not reach the coxal tuber, nor were they as high as the lumbar

transverse processes. It inserted by means of aponeurotic tissue to the coxal tuber, prepubic tendon and linea alba. The aponeurosis blended with the aponeurosis of the underlying *M. obliquus internus abdominis* to form the external sheath of *M. rectus abdominis*.

*M. obliquus internus abdominis* (Figs. 1/9, 2/1, 3,4/2 and 5/4) was situated beneath *M. obliquus externus abdominis*. Its fibers were directed ventral, cranial, and medial. It had triangular shape, the fleshy portion of this muscle was well developed and clearly fasciculated. It occupied the entire flank region from the coxal tuber to the last rib, where it was intermingled, more or less with the fibers of *M. retractor costae*. Its aponeurosis was divided into two distinct parts, The dorsal part was attached to the caudal border of the last rib and its cartilage. The ventral one extended laterally to the costal arch to fuse with the aponeurosis of *M. obliquus externus abdominis* which assisted in the formation of the external sheath of *M. rectus abdominis*. It originated from the coxal tuber and the deep lumbar fascia at the lateral border of *M. longissimus lumborum*, and inserted in the prepubic tendon and linea alba.

*M. rectus abdominis* (Figs. 1/11, 3/4, and 4/5) was confined to the ventral abdominal wall. It extended from the sternum to the pubis. It originated from the ventral border and lateral surfaces of the sternum as far cranial as the third or fourth costal cartilage. It inserted in the prepubic tendon and thus indirectly to the pecten of the pubis and the symphyseal ligament. There were five tendinous intersections in the cranial two thirds of the muscle which passed at right angles to the muscle fibers, prevented the muscle fibers from spreading and thus strengthen the muscle.

*M. transverse abdominis* (Figs. 1/10, 3/3, 4/4 and 5/3) was named from the general direction of its fibers. It could be seen as a muscular sheet on the deep face of *M. obliquus internus abdominis* and *M. rectus abdominis*. It originated from the deep lumbar fascia, and thus indirectly to the first five lumbar transverse processes, the medial surface of the false ribs meeting the costal attachment of the diaphragm, the transverse fascia and the caudomedial surface of the thirteenth rib. It inserted in the linea alba, the aponeurotic insertion was intimately associated with the peritoneum which assists in the formation of the internal sheath of *M. rectus abdominis*.

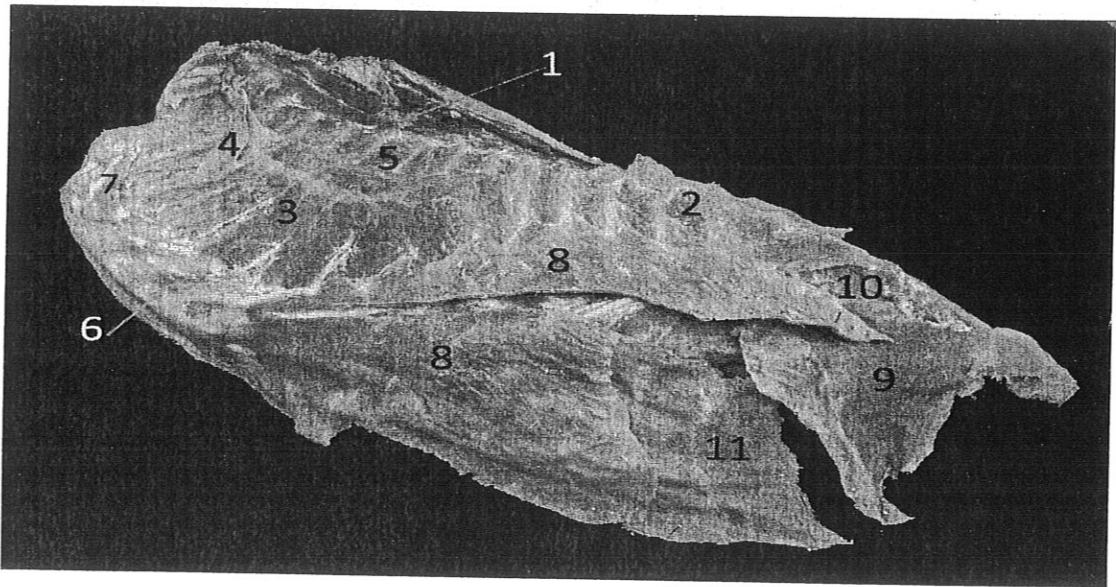


Fig. 1. A photomicrograph of plastinated trunk of the goat (left dorsolateral view) showing, 1- *M. serratus dorsalis cranialis*; 2- *M. serratus dorsalis caudalis*; 3- *M. serratus ventralis thoracis*; 4- *M. scalenus dorsalis*; 5- *Mm. intercostales externi*; 6- *Mm. intercostales interni*; 7- *M. rectus thoracis*; 8- *M. obliquus externus abdominis*; 9- *M. obliquus internus abdominis*; 10- *M. transverse abdominis*; 11- *M. rectus abdominis*.

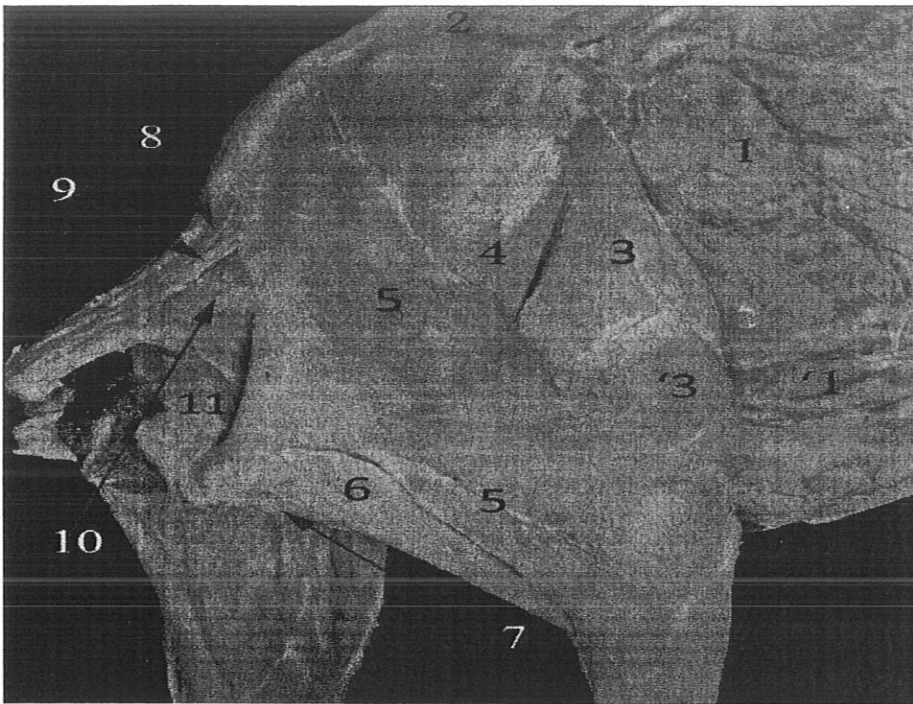


Fig. 2. A photomicrograph of goat (caudolateral view): showing; 1- M. obliquus internus abdominis; 1'- aponeurosis of 1; 2- M. longissimus lumborum; 3- M. tensor fasciae latae; 3'- fascia lata; 4 - M. gluteus medius; 5- M. gluteobiceps; 6- M. semitendinosus; 7- M. semimembranosus; 8- M. sacrocaudalis dorsalis medialis; 9- M. sacrocaudalis dorsalis lateralis; 10- M. coccygeus; 11- M. levator ani.




Fig. 3. A photomicrograph of plastinated trunk of the goat (lateral view) showing, 1- M. obliquus externus abdominis (reflected); 1'- aponeurosis of 1; 2 - M. obliquus internus abdominis; 2'- aponeurosis of 2; 3- M. transverse abdominis; 4- M. rectus abdominis; 5- M. serratus ventralis thoracis.

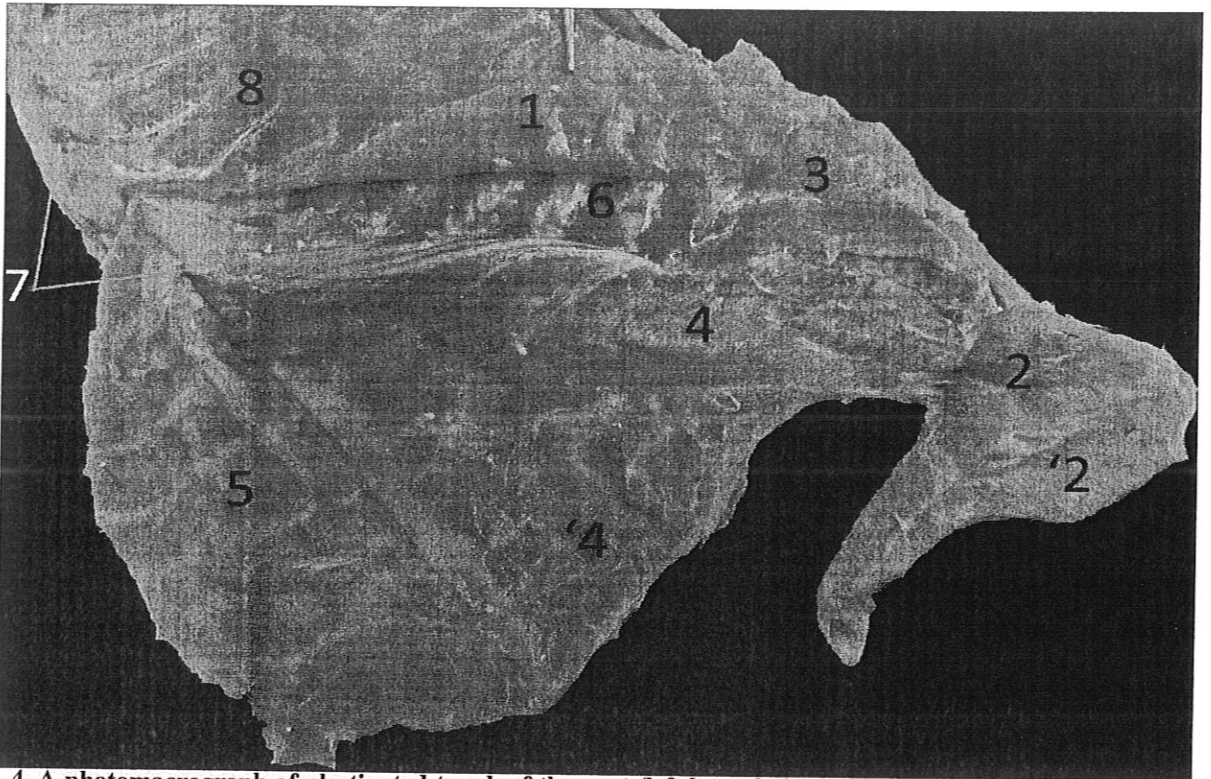


Fig. 4. A photomicrograph of plastinated trunk of the goat (left lateral view) showing, 1- *M. obliquus externus abdominis* (reflected); 2- *M. obliquus internus abdominis*; 2'- aponeurosis of 2; 3- *M. retractor costae*; 4- *M. transverse abdominis*; 4'- aponeurosis of 4; 5- *M. rectus abdominis* (reflected); 6- *Mm. intercostales externi*; 7- *Mm. intercostales interni*; 8- *M. serratus ventralis thoracis*.

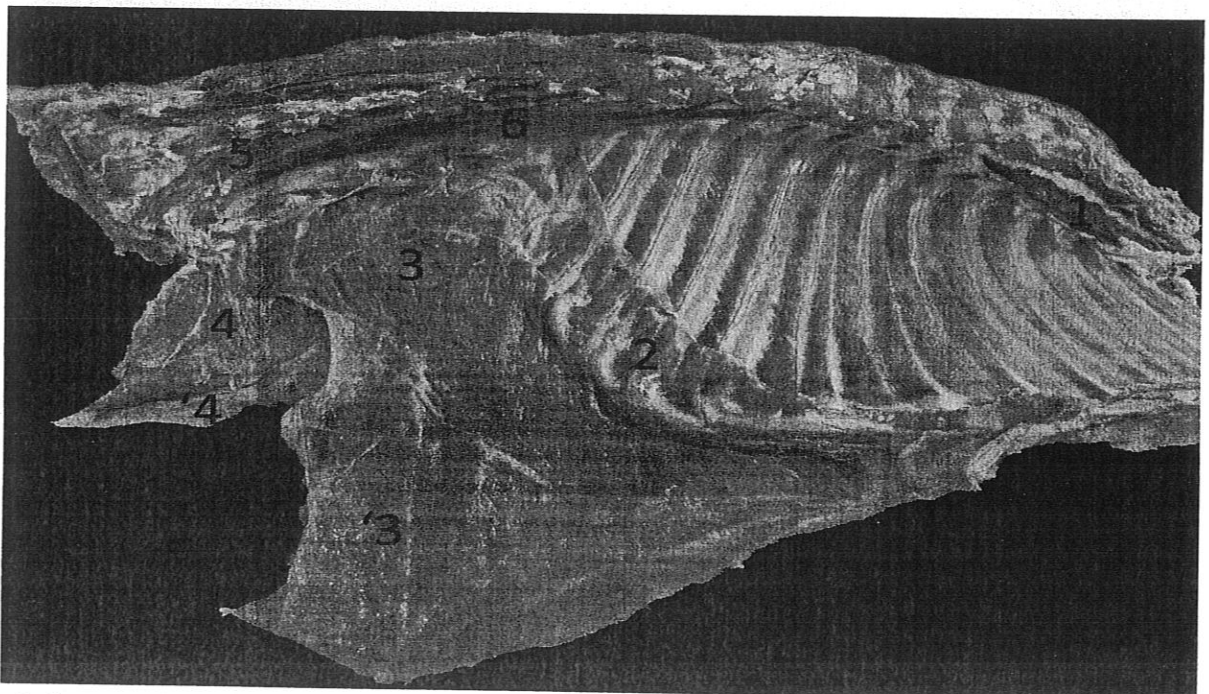


Fig. 5. A photomicrograph of plastinated trunk of the goat (medial view) showing, 1- *M. longus colli* (thoracic part); 2- Pars costalis of diaphragm; 3- *M. transverse abdominis*; 3'- aponeurosis of 3; 4- *M. obliquus internus abdominis*; 4'- aponeurosis of 4; 5- *M. psoas minor*; 6- *M. psoas major*.

## DISCUSSION

Our plastinated specimens of abdominal muscles were clean, dry, odorless and durable, more realistic, biologic specimens that could be handled without gloves and did not require any special storage conditions or care. These specimens also prevented exposure of staff and students to formaldehyde used in classical preservation of biological tissues (3, 13, 14).

Plastinated specimens should ideally be used as adjunct with cadaveric dissection for full appreciation of the interactions between body systems and to understand the body as one entity (15,16).

Due to costs, the beginning universities may not be able to maintain wet specimen dissection or may need to limit it severely. Plastinates were economically efficient teaching resources have a long lasting durability that can be reused year after year as additions to traditional teaching methods (17, 18).

The scientific value of using plastinated specimens in the teaching environment like in anatomy was hard to dispute. Use of such plastinated specimens gave students more enthusiasm and excitement to study. Besides this there may be students who were allergic to formaldehyde or afraid to touch the corpse placed in dissection halls. Use of plastinated specimens could be handled by these students easily. As well as, specimens could be handled and examined from all angles (17, 19,20).

Difficulties we found during plastination technique were related to the small-sized containers used in forced impregnation. These limitations hinder production of a whole goat specimen. Hopefully these difficulties could be overcome in the future by manufacture of large containers (13).

### Conclusion

Plastinated specimens were definitely ideal way for preserving biological tissues. It produced a long lasting, easily handlable, non hazardous and almost natural looking specimen which helped in teaching the anatomy of abdominal muscles of goat. Plastinated

specimens were also better options to be used in anatomy museums for self directed studies by students. Not only in anatomy, these specimens also proved beneficial in other specialties as, surgery, gynecology and internal medicine.

### Recommendation

Based on the findings of this study, it is recommended that we need for commencement of use of plastinated specimens to complement cadaveric materials at the anatomy department in our faculty.

As plastination science gradually enters the domain as an additional resource in departments of anatomy in medical colleges, teachers in anatomy are yet again provided with another vista for exploring their teaching and research skills in the various aspects of anatomy and other comparative studies.

## REFERENCES

1. Singh O, Mishra BK, Pandit S, Maheshwari T P and Hasan S (2013): Plastination: A Promising Method for Preserving Biological Specimens: A Review Article. International Journal of Scientific and Research Publications, Volume 3, Issue 6, Pp 2250-2253.
2. O'Sullivan E and Mitchell B S (1995): Plastination for gross anatomy teaching using low cost equipment, Surgical and Radiological Anatomy, 17(3):277-281.
3. Latorre R, Garcia-Sanz M P, Moreno M, Hernandez F, Gil F, Lopez O, Ayala MD, Ramirez G, Vazquez J M, Arencibia A and Henry R W (2007): How Useful Is Plastination in Learning Anatomy? JVME 34(2): 172 -176.
4. von Hagens G (1979): Impregnation of soft biological specimens with thermosetting resins and elastomers. Anat. Rec. 194:247.
5. Saeed M, Amin AR and Saleh EE (2001): 'Mummification to plastination', Saudi Medical Journal 22(11), 956-959.

- 6.Zaneb H and Stanek C (2007):** Three Rs in the research and education system of Pakistan: Perspectives and possibilities AATEX 14, Special Issue, 229-233 Proc. 6th World Congress on Alternatives & Animal Use in the Life Sciences August 21-25, , Tokyo, Japan.
- 7.Latorre R and Rodriguez M J (2007):** In search of clinical truths: equine and comparative studies of anatomy. Equine Veterinary Journal, 39, 263-268.
- 8.Mathur N and Rastogi S K (2007):** Respiratory effects due to occupational exposure to formaldehyde: Systemic review with meta-analysis. Indian Journal of Occupational and Environmental Medicine, 11, 26-31.
- 9.Jones RS (2008):** Combining local and general anesthesia for better pain relief in dogs and cats. Veterinary Journal, 178(2):161-162.
- 10. von Hagens G, Tiedemann K and Kriz, W (1987):** The current potential of plastination. Anat. Embryol. (Berl.); 175 (4):411-421.
- 11.Basset Aly A E (2006):** Procedures of plastination. Department of Anatomy and Embryology, Zagazig University: 1-5.
- 12.Nomina Anatomica Veterinaria (2012):** 5th edition, prepared by the International Committee on Veterinary Gross Anatomical Nomenclature (I.C.V.G.A.N.) and authorized by the General assembly of the World Association of Veterinary Anatomists (W.A.V.A.), Knoxville, TN (USA). Published by the Editorial Committee, Hannover, Columbia, Gent and Sapporo pages 39-48.
- 13.El-Nandy FAO (1999):** Modern educational technology in teaching veterinary anatomy with special references to applications practice. Ph.D. Thesis, Vet. Med., Cairo University.
- 14.Azu OO, Peter AI, Etuknwa BT and Ekandem GJ (2012):** 'The Awareness of Medical Students in Nigerian Universities about the Use of Plastinated Specimens for Anatomical Studies', Macedonian Journal of Medical Sciences 5(1), 5-9.
- 15.Sugand K, Abrahams P and Khurana A (2010):** 'The Anatomy of Anatomy: A Review for Its Modernization', Anatomical Sciences Education 3, 83-93.
- 16.Azu OO, Peter AI, Aquaisua A N and Ekandem, GJ (2013):** Plastination technology for anatomical studies in Nigeria: Opinion of teachers at medical institutions. Health SA Gesondheid, Journal of Interdisciplinary Health Sciences, 18(1), 664-670.
- 17.KC N, Priya K, Lama S and Magar A (2007):** Plastination - an unrevealed art in the medical science. Kathmandu University Medical Journal Vol. 5, No. 1, Issue 17, 139-141.
- 18.Baker EW, Slott PA, Terracio L and Cunningham E P (2013):** An Innovative Method for Teaching Anatomy in the Predoctoral Dental Curriculum. Journal of Dental Education, Volume 77, Number 11, 1498- 1507.
- 19.Basset Aly, A E, Soliman Kh, Abdel Aziz A, Abdel Aziz S, Nosiur H, Konsowa M and Aly H (2008):** Education of Veterinary Anatomy by Plastination. The 14th International Conference on Plastination. 20-26 July, 2008 Heidelberg & Guben.
- 20.Basset Aly, A E, Soliman Kh, Selim A, Abdel Aziz S, Nosiur H, Konsowa M.; Omar A, Hilal, A, Atia A, Khairy S and Elhadi E (2011):** Use of plastinated camel Brains as Neuroanatomy Teaching Aids. The 10th International Interim on Plastination. 9-12 July, 2011 Toledo, Ohio, USA.

### المخلص العربي

#### العضلات البطنية المعاملة بلاستيكية في الماعز كاتجاه مستقبلي في تدريس التشريح

على الدين عبد الباسط على، حسن أنيس محمد، أحمد محمد السيد أحمد عمر، إيناس الهادي أحمد أحمد  
قسم التشريح وعلم الأجنة- كلية الطب البيطري- جامعة الزقازيق

ان تطبيق تقنية البلمستكة كمصدر جديد في تدريس تشريح العضلات البطنية له أهمية قصوى خاصة في ظل تساؤل الجثث المستخدمة في التعليم الطبي البيطري في مصر وذلك بسبب التكلفة الباهظة للحيوانات. لذلك نحن في حاجة لزيادة الاقبال على استخدام العينات المعاملة بلاستيكية كمكمل للجثث لاتمام تعليم وتعلم التشريح البيطري. الهدف من هذا البحث هو توصيف طريقة عمل عينات معاملة بلاستيكية للعضلات البطنية في الماعز لتستخدم في أغراض تعليمية. إن الفهم الجيد لتشريح العضلات البطنية له علاقة وطيدة بعلم التناسليات في الاناث وعلم الجراحة وعلم الأمراض الباطنية. ومن نتائج هذا البحث نستنتج أن استخدام العينات المعاملة بلاستيكية يعد طريقة ممتازة لتدريس العضلات البطنية في الماعز.